



Case Report

Accelerated patellofemoral joint erosion: A complication of isolated resurfacing of an arthritic patella with a polyethylene component



Hui-Kuang Huang^{a,b}, Cheng-Fong Chen^{b,c}, Chao-Ching Chiang^{b,c}, Ching-Kuei Huang^{b,c}, Wei-Ming Chen^{b,c,*}, Chien-Lin Liu^{b,c}

^a Department of Orthopedics, Chiayi Christian Hospital, Chiayi, Taiwan, ROC

^b National Yang-Ming University, Taipei, Taiwan, ROC

^c Department of Orthopedics and Traumatology, Taipei Veterans General Hospital, Taipei, Taiwan, ROC

ARTICLE INFO

Article history:

Received 24 April 2013

Received in revised form

23 May 2013

Accepted 13 June 2013

Available online 15 November 2013

Keywords:

arthritis

arthroplasty

hemiarthroplasty

isolated resurfacing

patellofemoral

ABSTRACT

Patellofemoral arthrosis is commonly encountered in clinical practice. This morbid condition can critically affect the patient's quality of life. Many treatments have been reported to address this problem, including operative and nonoperative modalities. Patellofemoral arthroplasty had been reported to have an excellent outcome in some reports, although the treatment is still controversial. We report a case of a complication that arose after isolated resurfacing of an arthritic patella with a polyethylene component. Serious femoral cartilage wear with severe synovitis was noted in the early postoperative period. Clinicians are therefore cautioned to avoid isolated patellar resurfacing for treating patellofemoral arthritis.

Copyright © 2013, Taiwan Orthopaedic Association. Published by Elsevier Taiwan LLC. All rights reserved.

1. Introduction

Treatments for patellofemoral (PF) arthrosis have been debated in recent years. There are a variety of operative and nonoperative modalities to treat PF arthrosis. Nonoperative treatment using physiotherapy, taping, or injection therapy may result in short-term relief. Joint-preserving surgical treatment—including tubercle realignment, patellectomy, cartilage transplant—may result in insufficient, unpredictable, or only short-term improvement.¹ Meanwhile, PF arthroplasty for treating isolated PF arthritis remains controversial. The outcome after PF arthroplasty in selected patients ranges from good to excellent in some short-term follow-up studies.^{2–4} We report on a patient who had undergone “hemiarthroplasty”—isolated resurfacing of an arthritic patella with a polyethylene component for treating PF osteoarthritis. The complication happened rapidly after the procedure, reflecting

poor judgment. The patient gave permission for her case to be published.

2. Case report

A 71-year-old woman presented to our clinic with the complaint of severe pain in her right knee. Her history showed that she had right anterior knee pain for at least 5 years, especially during squatting motion. She went to an orthopedic clinic for evaluation. An X-ray scan of her right knee showed PF osteoarthritis and lateral deviation of the patella (Fig. 1). It was suspected that the pain was caused by the PF problem, so the clinician performed PF “hemiarthroplasty” to treat the problem by only replacing the patellar component. After the surgery, her discomfort was slightly alleviated, but then became worse rapidly. The pain caused by flexing the knee persisted and she could even do less flexion postoperatively. Eventually, it came to the point where she could hardly walk even after taking painkillers. She came to our clinic 3 years after that operation. The physical examination demonstrated right knee effusion with a limited range of motion (0–90°). Severe patellar grinding pain was noted, and an X-ray revealed severe osteolysis of the unresurfaced femoral part.

* Corresponding author. Department of Orthopedics and Traumatology, Taipei Veterans General Hospital, 201, Section 2, Shih-Pai Road, Taipei 112, Taiwan, ROC. Tel.: +886 2 28757557; fax: +886 2 28344950.

E-mail address: wmchen@vghtpe.gov.tw (W.-M. Chen).

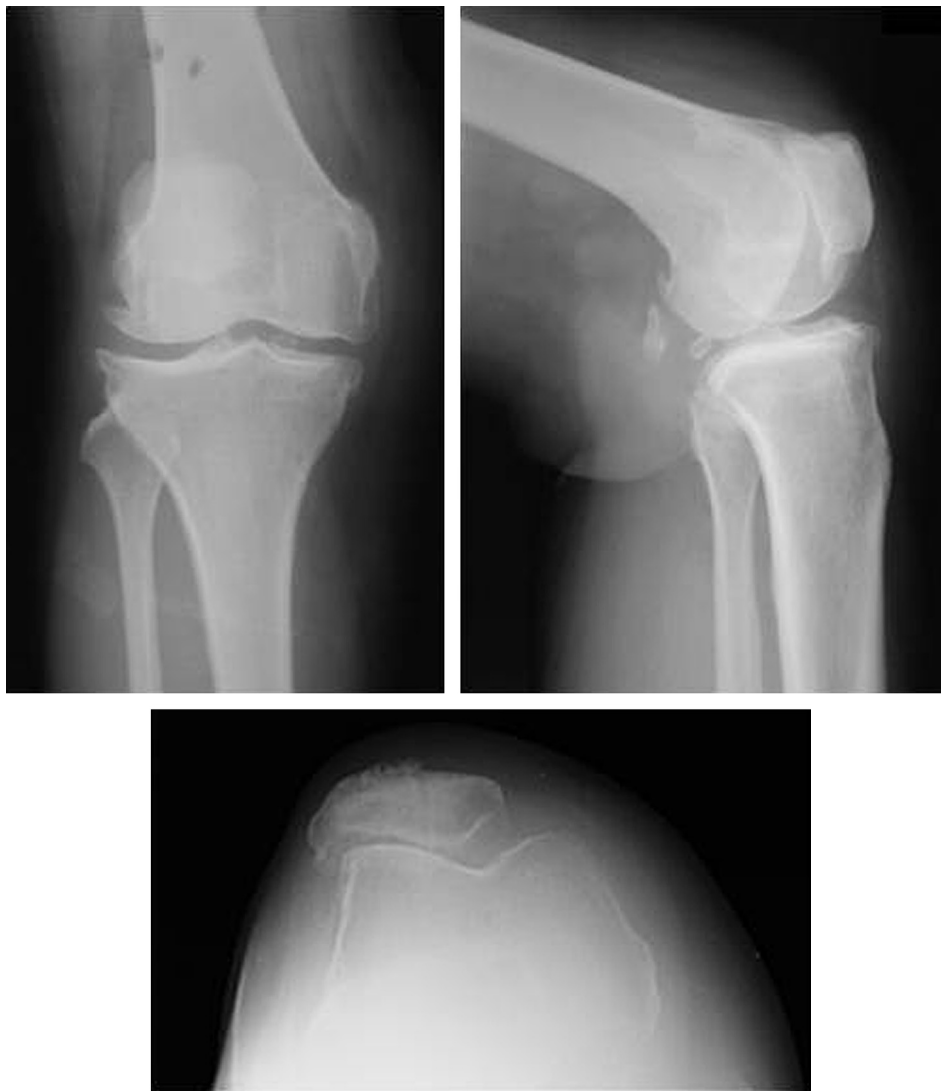

Fig. 1. Right knee patellofemoral component osteoarthritis with patella lateral deviation and femorotibial osteoarthritis.

Femorotibial osteoarthritis was also seen (Fig. 2). The patient then underwent total knee arthroplasty with patellar component revision in our institute (Fig. 3). Severe wear of the femoral cartilage and patellar polyethylene surface were seen during the operation. Severe synovitis was also seen (Fig. 4). No infection was identified from the microorganism culture taken intraoperatively. After the surgery, the range of motion of 0–140° and improved pain were noted during follow-up.

3. Discussion

Failure of PF arthroplasty often occurs because of implant malalignment or progression of femorotibial compartment osteoarthritis.⁵ We found that the patient had more wear on the lateral side of the femur (Figs. 2 and 4). This could be the consequence of a malposed patellar component or a malbalanced soft tissue.⁶ The preoperative anteroposterior radiograph showed lateral tilting of the patella. Thus, more emphasis on the patellar position setting and soft tissue balance was necessary in this case. Preoperative X-ray evaluation and intraoperative patellar tracking

balance are very important when dealing with a PF problem by arthroplasty.

The patellar thickness after patellar resurfacing is also an important factor. A thin patella can minimize the contact force of the PF joint, but it increases the risks of patellar fracture and anteroposterior instability. By contrast, a thick patella can increase the effective quadriceps moment arm at low flexion angles of the knee, but it reduces the knee's range of motion.⁷ We assumed that the patellar component might have become thicker after the surgery, so the strong contact force could have limited her flexion and induced the cartilage of the femoral side to wear out fast.

Patellar resurfacing in total knee arthroplasty continues to be a source of debate. Patients with well-tracking extensor mechanism, minimal patellar arthritis, and patellar-friendly femoral components may be candidates for patellar resurfacing.^{8,9} In total knee arthroplasty without patellar resurfacing, further patellar related pain or complications would lead to additional surgery. But with good patient selection and meticulous correction of the mechanical deformity, patellar complications can be minimized.

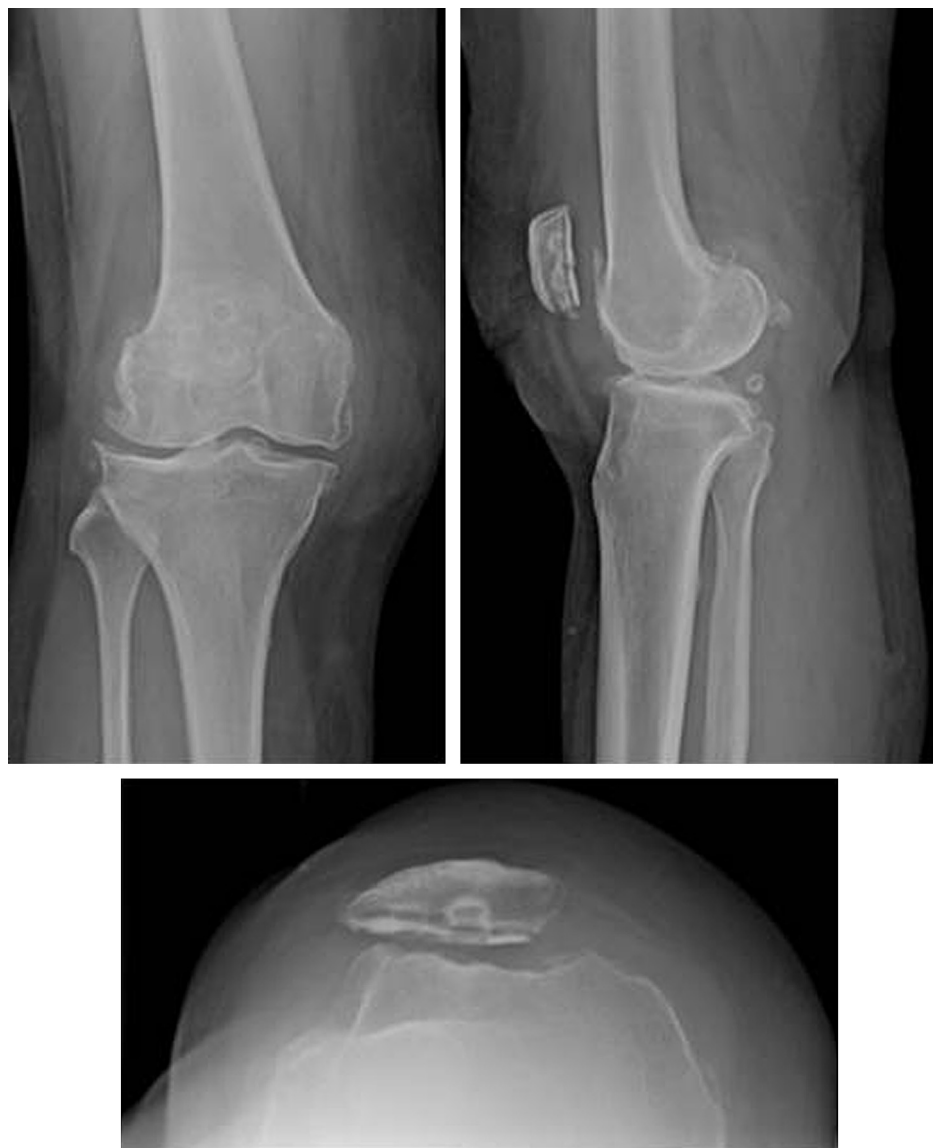

Fig. 2. Resurfaced patella and severe femoral contact area wear.

For cases of PF arthroplasty only, further surgery would be required if the PF component fails or femorotibial arthritis develops. However, in selected patients with PF problems only, it appears that a satisfactory outcome could be achieved by a well-performed PF arthroplasty.² In this case, severe patellar polyethylene wear and cartilage erosion were seen. This proved that polyethylene did not articulate well with the femoral articular part in this hemiarthroplasty procedure. We supposed that the original surgeon might come up with this idea from the hemiarthroplasty of the hip. But in treating PF arthritis, isolated patellar surfacing will not succeed if the opposite femoral arthritis exists. The inadequate tracking and the deformed knee axis due to degeneration would accelerate the polyethylene wear and cartilage erosion. Also, the poorly articulated PF joint makes the wear and erosion more rapid because the reaction force is not well distributed.¹⁰ In the hemiarthroplasty procedure, what the clinician can do is to only adjust the location of polyethylene on a

small patella. However, it will be impossible to adequately address all these problems.

There were several treatments considered for the initial treatment of this patient. In addition to nonoperative methods, Maquet osteotomy or PF arthroplasty could be the operative choice to treat her PF problem.^{4,11–13} However, further revision to total knee arthroplasty would be a possibility because of the femorotibial osteoarthritis seen in the initial X-ray examination (Fig. 1). Of course, total knee arthroplasty could be considered for her initial treatment. The rate of further reoperation due to complications or prosthesis wear will be minimized. In this case report, we describe a complication that arose after hemiarthroplasty by isolated resurfacing of an arthritic patella with a polyethylene component. This type of treatment will cause rapid femoral cartilage wear and require further reoperation. Moreover, the arbitrary adaptation of groundless procedures also raises concerns about violation of medical ethics.

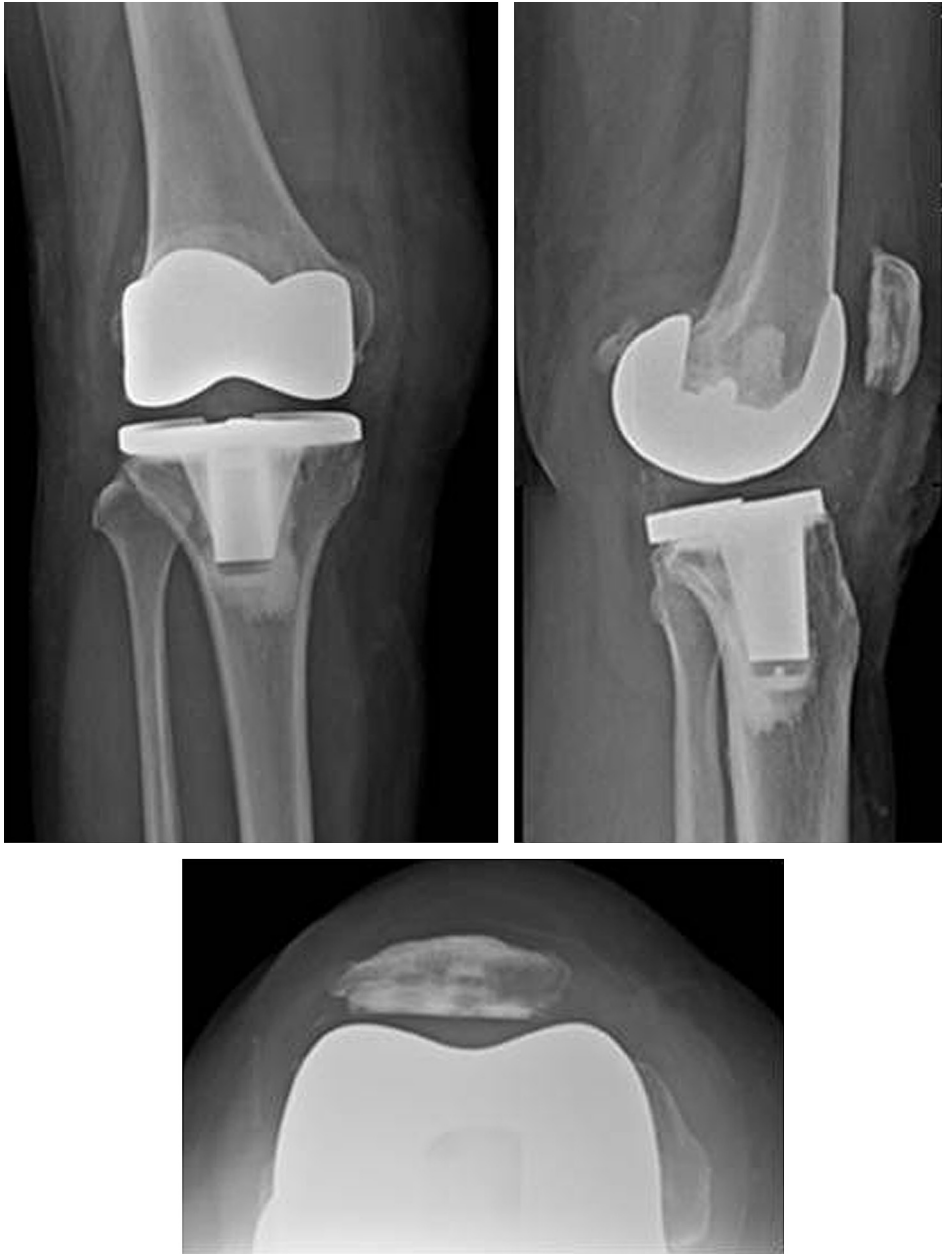

Fig. 3. Radiographs after total knee arthroplasty and patellar component revision.

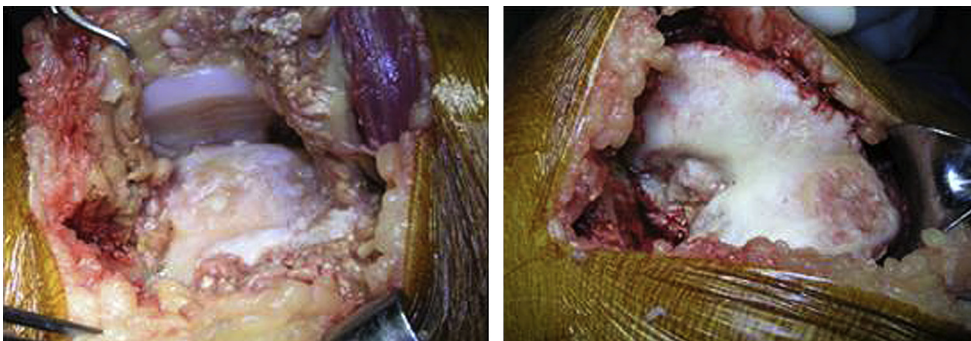


Fig. 4. With medial parapatellar approach, the joint showed severe synovitis, patellar polyethylene wear, and femoral cartilage wear.

References

1. J.P. Fulkerson. Alternatives to patellofemoral arthroplasty. *Clin Orthop Relat Res* 436 (2005) 76–80.
2. W.B. Leadbetter, F.R. Kolisek, R.L. Levitt, A.F. Brooker, P. Zietz, D.R. Marker, P.M. Bonutti, et al. Patellofemoral arthroplasty: a multi-centre study with minimum 2-year follow-up. *Int Orthop* 33 (2009) 1597–1601.
3. M. Odumanya, M.L. Costa, N. Parsons, J. Achten, M. Dhillon, S.J. Krikler. The avon patellofemoral joint replacement: five-year results from an independent centre. *J. Bone Joint Surg Br* 92 (2010) 56–60.
4. H.P. van Jonbergen, R.W. Poolman, A. van Kampen. Isolated patellofemoral osteoarthritis. *Acta Orthop* 81 (2010) 199–205.
5. S.G. Nicol, J.M. Loveridge, A.E. Weale, C.E. Ackroyd, J.H. Newman. Arthritis progression after patellofemoral joint replacement. *Knee* 13 (2006) 290–295.
6. D.D. Rhoads, P.C. Noble, J.D. Reuben, O.M. Mahoney, H.S. Tullos. The effect of femoral component position on patellar tracking after total knee arthroplasty. *Clin Orthop Relat Res* 260 (1990) 43–51.
7. H.C. Hsu, Z.P. Luo, J.A. Rand, K.N. An. Influence of patellar thickness on patellar tracking and patellofemoral contact characteristics after total knee arthroplasty. *J Arthroplasty* 11 (1996) 69–80.
8. R.B. Bourne, R.S. Burnett. The consequences of not resurfacing the patella. *Clin Orthop Relat Res* 428 (2004) 166–169.
9. R.S. Burnett, C.M. Haydon, C.H. Rorabeck, R.B. Bourne. Patella resurfacing versus nonresurfacing in total knee arthroplasty: results of a randomized controlled clinical trial at a minimum of 10 years' followup. *Clin Orthop Relat Res* 428 (2004) 12–25.
10. H.M. Ma, Y.C. Lu, T.G. Kwok, F.Y. Ho, C.Y. Huang, C.H. Huang. The effect of the design of the femoral component on the conformity of the patellofemoral joint in total knee replacement. *J Bone Joint Surg Br* 89 (2007) 408–412.
11. L.H. Rappoport, M.G. Browne, T.L. Wickiewicz. The maquet osteotomy. *Orthop Clin North Am* 23 (1992) 645–656.
12. F. Schmid. The maquet procedure in the treatment of patellofemoral osteoarthritis. Long-term results. *Clin Orthop Relat Res* 294 (1993) 254–258.
13. R. Mohammed, T. Jimulia, K. Durve, M. Bansal, M. Green, D. Learmonth. Medium-term results of patellofemoral joint arthroplasty. *Acta Orthop Belg* 74 (2008) 472–477.